

CASO 1

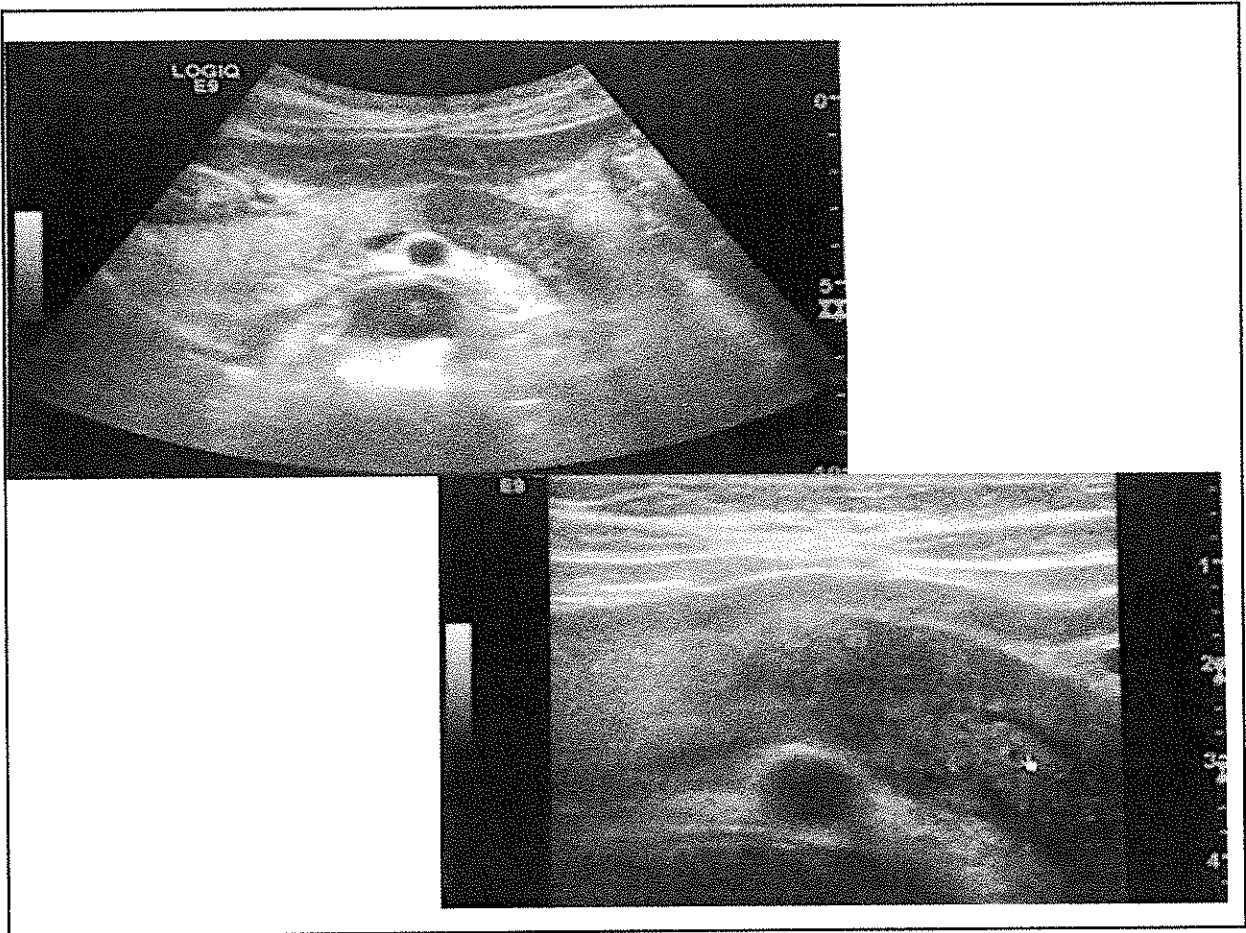
57 AA - M

Ittero e calo ponderale (circa 4 kg nell'ultimo mese).

Comorbidità: DM di recente insorgenza.

The image shows three handwritten signatures in black ink. The first signature on the left is a cursive name that appears to be 'M. Rossi'. The second signature in the middle is a stylized, possibly illegible mark. The third signature on the right is a more complex cursive signature, possibly 'G. Rossi'.

ALL. CASO 1




[Handwritten signature]

CASO 2

73 AA - F

Ricoverato per ittero ingravescente da 15 giorni e feci ipocoliche con urine ipercromiche da 4 giorni. Al momento del ricovero Bil. 18,1 mg/dL di cui diretta 12.2 mg/dL. PCR 1.64 mg/dl.

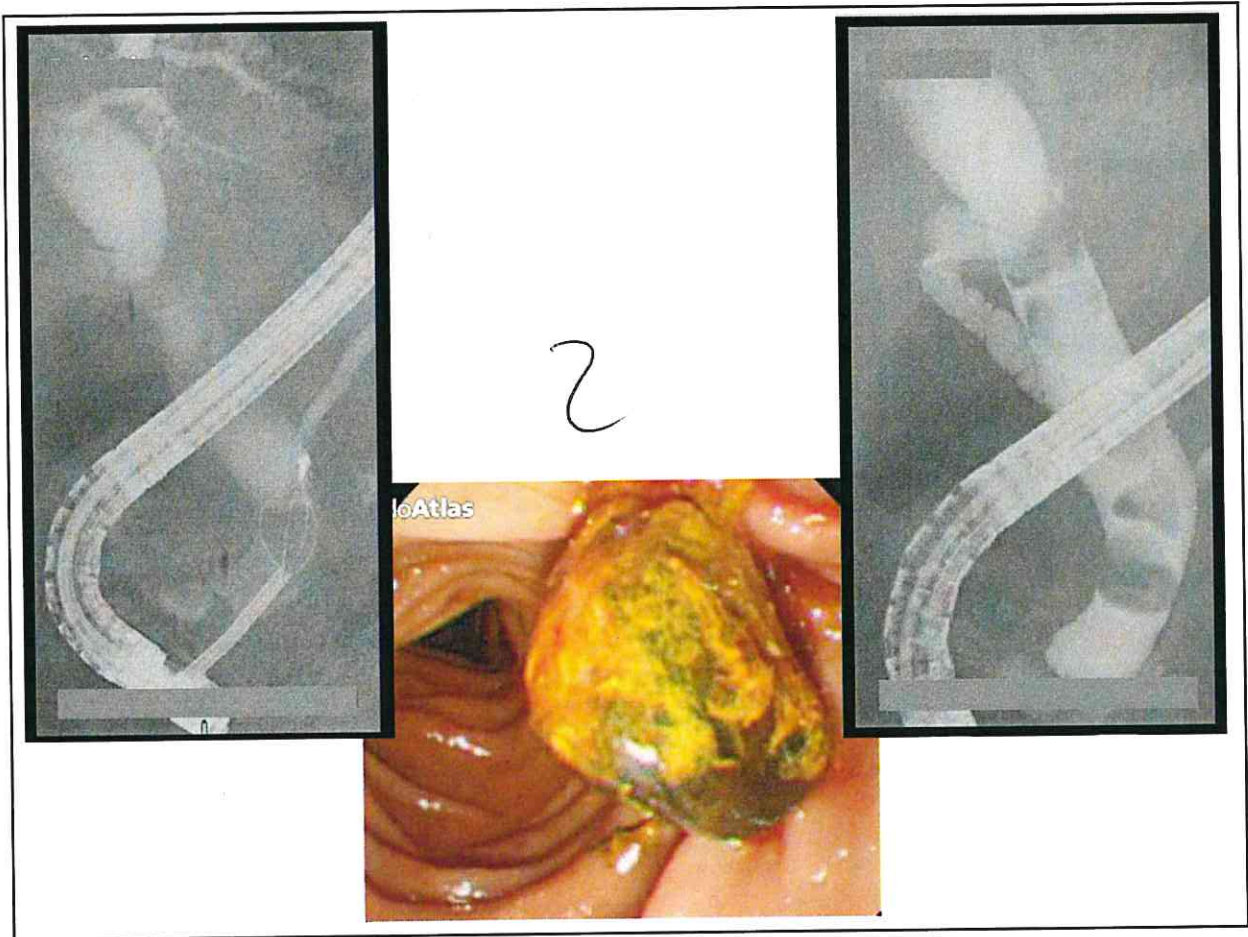
Comorbidità: ipertensione arteriosa, sovrappeso.

The image shows four handwritten signatures in black ink, arranged in two pairs. The first pair on the left consists of a large, stylized signature and a smaller one above it. The second pair on the right also consists of a large, stylized signature and a smaller one above it.

ALL. CASO 2

1

3



2

Adell
R
D
P

CASO 3

53 AA - M

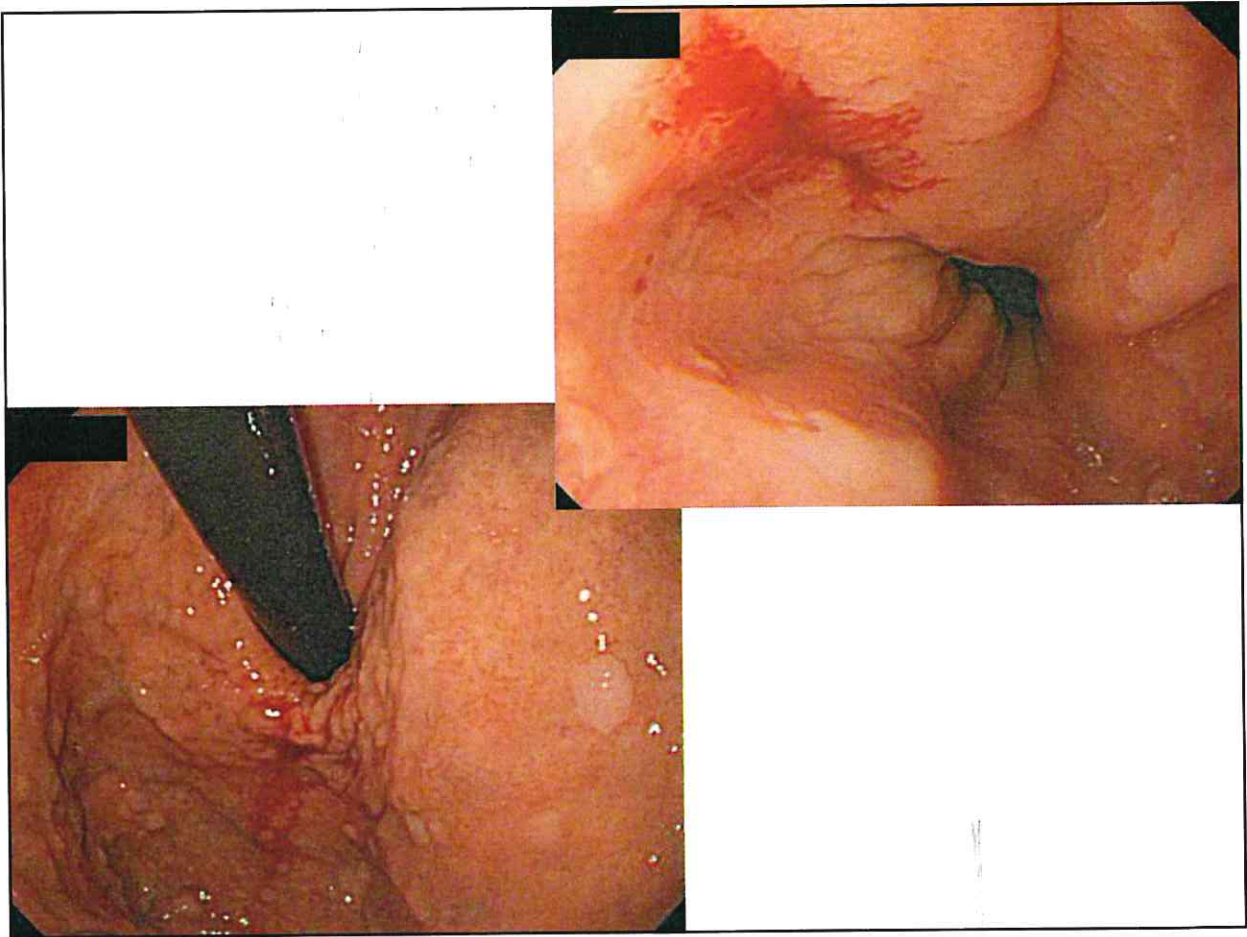
Ricoverato per ematemesi e melena.

Comorbidità: ipertensione arteriosa e cardiopatia ischemica.
Assume cardioaspirina

Handwritten signatures and initials:

- Top left: "R"
- Top middle: "M"
- Top right: "MS"
- Bottom left: "Gall"
- Bottom middle: "Gall"
- Bottom right: "Gall"

ALL. CASO 3



Re
All
AD
MS