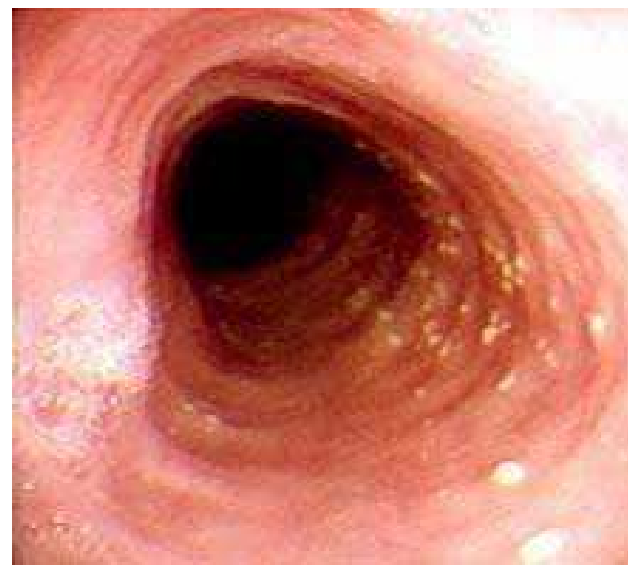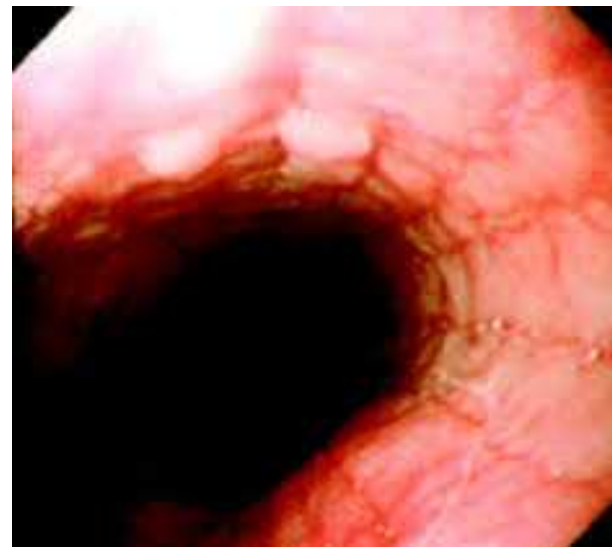

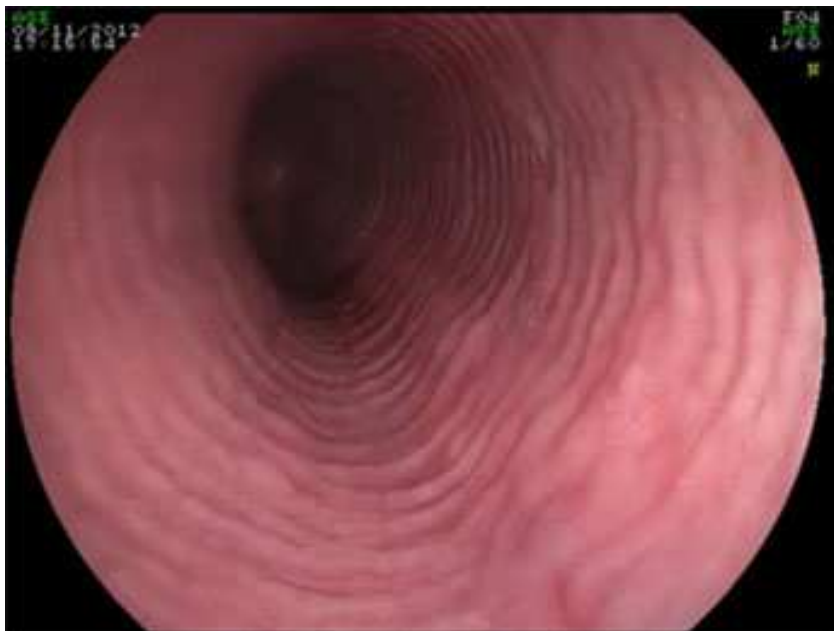
CASO 1

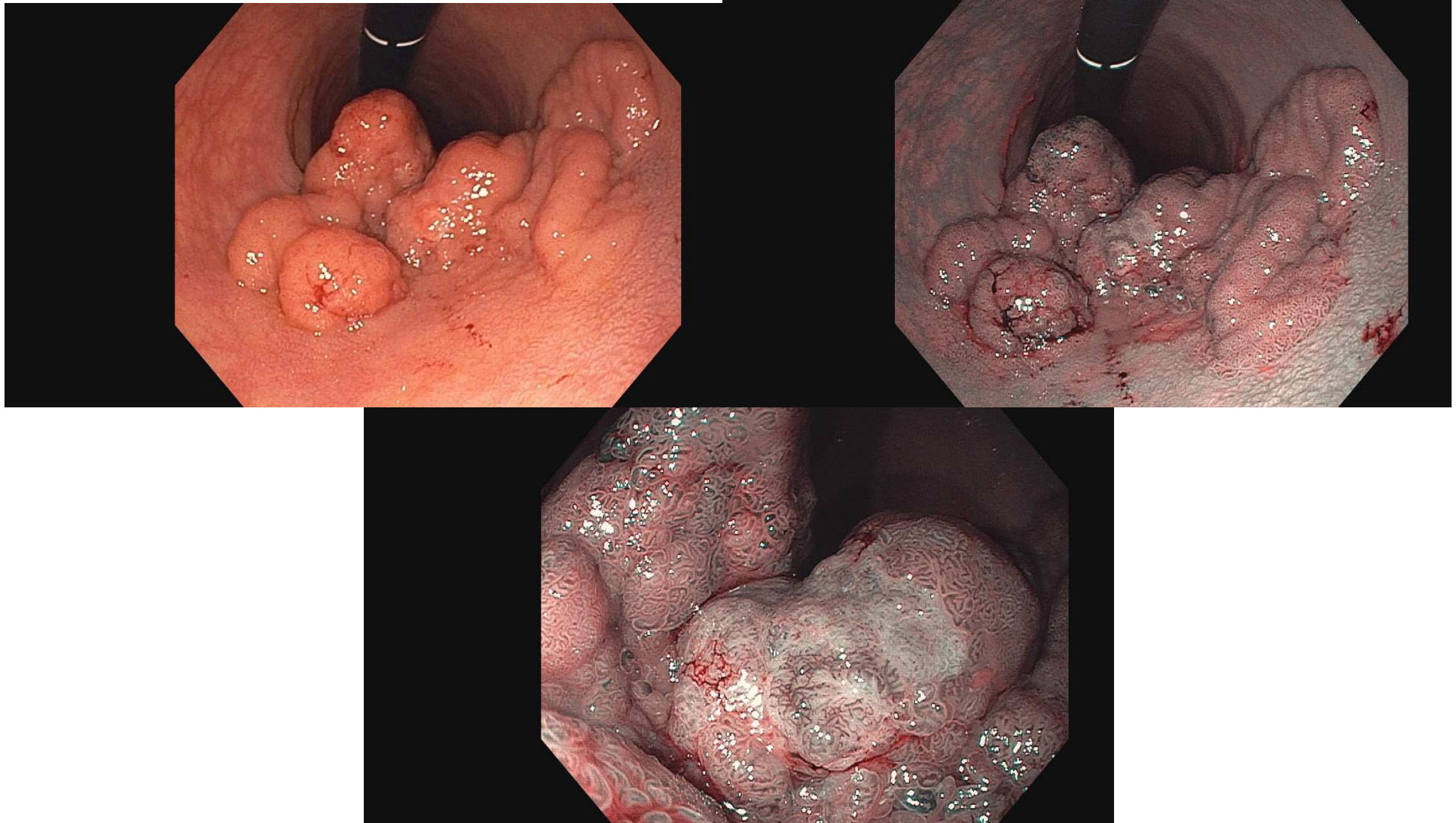


Disfagia

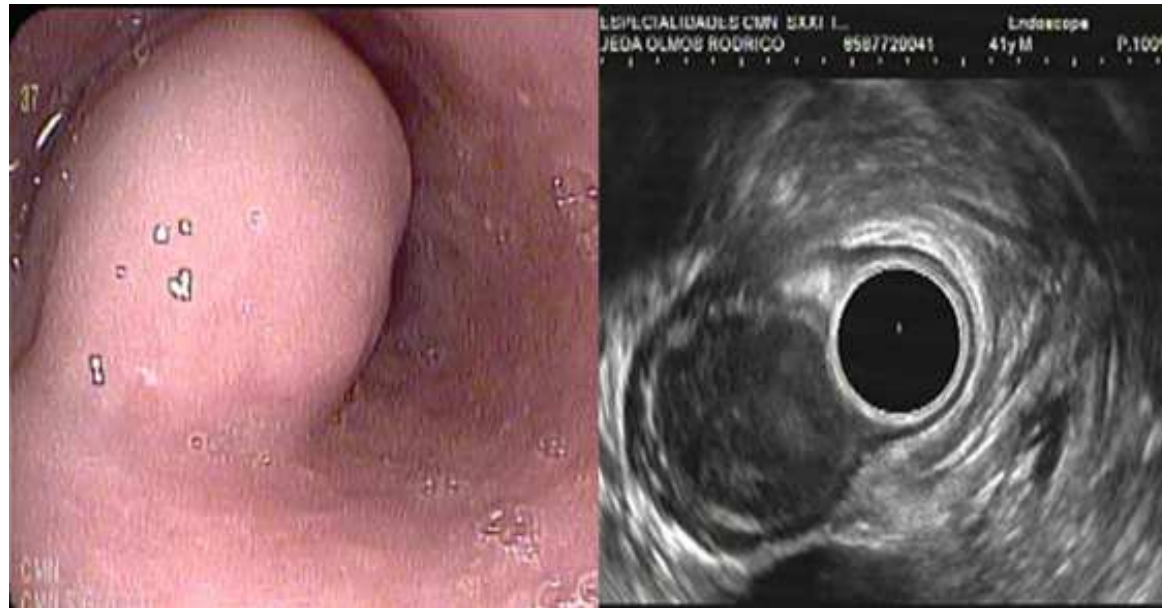
Impatto di bolo alimentare risolto spontaneamente

CASO 2

FIT +
Esegue colonscopia di screening



CASO 3



Alla EGDs per dispesia riscontro in stomaco di formazione protrudente ricoperta da mucosa regolare